

Comparative study between absorbable and Non-Absorbable nasal packings after nasal surgeries

Ayman Abdelaal Mohamady, Hossam Abdelhay Gad, Ashraf Salah El-Hamshary, Dalia Ragab Abd-Elmaksoud, Abd-Elhakeem Fouad Ghallab

Department of ORL, Faculty of Medicine, Benha University, Benha, Egypt

Correspondence to Dalia Ragab Abd-Elmaksoud, MBBS, Department of ORL, Faculty of Medicine, Benha University, Benha 79371, Egypt

Fax: 01003753650,

Postal code: 02

e-mail: drahmedsaeedkhater@gmail.com

Received 01 July 2020

Revised 22 July 2020

Accepted 04 August 2020

Published 21 January 2021

Pan Arab Journal of Rhinology

2020, 10:105–117

Background

Nasal packing is frequently used after nasal surgeries to control bleeding and prevent adhesions. Many absorbable packing materials have been developed to avoid the drawbacks of the traditional nonabsorbable ones and to help in wound healing.

Objective

This study was done to compare between absorbable and nonabsorbable nasal packings regarding patient satisfaction and clinical outcome.

Patients and methods

A prospective, single-blinded, randomized controlled clinical study was carried out in Benha University Hospital from May 2018 to November 2019. A total of 40 patients (80 nostrils) were enrolled in this study undergoing surgery. At the end of the procedure, the operative cavity of each patient was randomly packed with Merocel, as a nonabsorbable material on one side, and an absorbable material, which was sinufoam or gelfoam, on the other side. Patients' symptoms, including pain, nasal obstruction, and nasal discharge, were evaluated with a visual analog scale. Objective findings about bleeding, crustations, adhesions, infection, and mucosal edema were evaluated endoscopically. Each evaluation was done at third day, 2 weeks, 4 weeks, 6 weeks, and 12 weeks after surgery.

Results

Absorbable packings had minimal pain, less nasal obstruction scores, and lower incidence of discharge. Bleeding was significantly higher on absorbable side early postoperatively, especially with Gelfoam. Crustation and adhesion scores were significantly higher on Merocel-packed sides. Gelfoam showed crustations and adhesions more than Sinufoam. Mucosal edema score was significantly higher in Merocel group than the absorbable. However, there was no difference at 6 and 12 weeks. Gelfoam showed only significantly higher edema than Sinufoam at 6 weeks. There was a significant difference between absorbable group and Merocel regarding infection at 1 and 2 weeks. There was no difference between Gelfoam and Sinufoam regarding infection except at 6 weeks.

Conclusion

Absorbable packings are associated with less discomfort, more bleeding, and fewer complications.

Keywords:

absorbable packings, gelfoam, nasal surgeries, and sinufoam,

Pan Arab J Rhinol 10:105–117

© 2021 2090-7640

Introduction

Nasal packing materials are generally used in various endonasal surgical procedures, including septoplasty, turbinoplasty, and paranasal sinus surgeries. Nasal packs are intended to give hemostasis after epistaxis or surgical procedures; support the cartilaginous and bony nasal structure, nasal conchae or soft tissue (e.g., sliding flaps); and prevent synechiae or stenosis, particularly following sinus procedures [1].

Conventional nasal packings incorporate those regularly utilized removable materials like dressing, cotton, and sponge, regardless of whether they are coated by glove fingers or any chemicals [2].

These packings have a few favorable circumstances including availability, modest cost, simple control, and

adequate supporting capacity. Anyway, conventional packings are censured for their different downsides such as nasal airway blockage, pressure headache, painful mouth, and pharynx dryness because of prolonged mouth breathing. What is more, prolonged packing time may cause infection [3].

Removal of nasal packs is regularly the most painful part of surgical procedure for patients. The pain might be brought about by dislodgement of the blood clot and adherent tissues or following adherence of traditional nasal tampons to the first bleeding site [4]. Moreover,

This is an open access journal, and articles are distributed under the terms of the Creative Commons Attribution-NonCommercial-ShareAlike 4.0 License, which allows others to remix, tweak, and build upon the work non-commercially, as long as appropriate credit is given and the new creations are licensed under the identical terms.

nasal packing additionally requires a hospital stay and administration of antibiotics and it meddles with nasal physiology. Moreover, packing removal can cause mucosal damage bringing about bleeding. These drawbacks related with removable nasal packings have prompted continuous advancement of biodegradable/absorbable materials not requiring ensuing removal [5].

There is no commonly perceived standard for what sorts of materials ought to be utilized, for how long packs ought to stay put, or when indicated, nasal packs ought to apply pressure, function as a barrier, fill performed spaces, or create moist environment to facilitate physiological hemostatic and reparative processes [1,6].

Sinuf foam (ArthroCare) (Stammberger's SinuFoam) is a foam/gel produced using carboxy methylcellulose (CMC) derivative. CMC can absorb many times its weight in water. In the gel form, it has just been hydrolyzed preceding placement in the nasal cavity. In this way, in spite of the fact that it accomplishes some hemostasis by absorbing water in blood, it basically accomplishes hemostasis by pressure. It likewise gives a moist environment for wound and with its viscosity and thickness, gives a scaffold for epithelialization [5].

CMC is a plant-sourced polysaccharide biomaterial that is an intense activator of the coagulation cascade and is in the form of a mesh, foam, or gel [7].

Aim

This study was done to compare the efficacy of the absorbable nasal packings (Sinuf foam or Gelfoam) and nonabsorbable Merocel on wound healing and patient satisfaction.

Patients and methods

Patients

We enrolled 40 patients (80 nostrils) undergoing different nasal surgeries at Benha University Hospital, in a prospective, single-blinded, randomized controlled study between May 2018 and November 2019. Inclusion criteria were age between 18 and 45 years, with deviated septum and/or hypertrophied inferior turbinate, bilateral chronic rhinosinusitis requiring surgery, and a difference of two or less in the Lund-MacKay computed tomography scan. Exclusion criteria were history of previous nasal surgery, unilateral disease or massive sinonasal polyposis in patients with rhinosinusitis, and other underlying

diseases (diabetic, hypertensive, hepatic, coagulation disorder, immunodeficient) that may affect outcomes. Approval from the Ethical Committee of ENT Department, Benha University was obtained. In addition, informed consent was obtained from all patients before enrollment.

Study design

As the difference between Sinuf foam/Gelfoam and Merocel was obvious, we proceeded as a single-blinded study. Patients were randomized to determine which side was to receive absorbable packing (CMC/gelfoam) intraoperatively. The other side received nonabsorbable packing (merocel) at the time of procedures. Groups were as follows:

- (1) Group I: 40 nasal openings with absorbable nasal packing
- (2) Group II: 40 nasal openings with nonabsorbable nasal packing.

Group I was randomly divided into either of the following:

- (1) Gelfoam group: 20 patients (20 nasal openings) with Gelfoam on the absorbable side and Merocel on the other side
- (2) Sinuf foam group: 20 patients (20 nasal openings) with Sinuf foam (Stammberger's SinuFoam) on the absorbable side and Merocel on the other side.

Preoperative evaluation of patients was done through a full history, clinical examinations, nasal endoscopy, radiological, and laboratory investigations.

Materials

SINUFOAM (Stammberger's SinuFoam) is a CMC-based dressing, which begins as a dry CMC fiber inside a syringe. When appropriately blended in with sterile water, the CMC gels to form a viscous dissolvable foam that adjusts to the nasal cavities while giving a moist, hydrocolloid physical barrier (Fig. 1a-c).

Gelfoam (cutanplast, absorbable hemostatic gelatin sponge) is porous, water-insoluble hemostatic agent (Fig. 2a and b).

Merocel (polyvinyl acetate) is the widespread traditional non-absorbable material composed of hydroxylated polyvinyl acetate

Operative procedure

Patients underwent nasal surgeries including septoplasty (SMR) and/or inferior turbinoplasty or functional endoscopic sinus surgery (FESS). The operative procedures were performed under general anesthesia by senior staff members.

SMR was carried out with resection of most of the deviated cartilaginous and bony septum with or without inferior turbinoplasty. Internal nasal splints were inserted into both nasal cavities and fixed by 3-0 Vicryl sutures.

Surgical procedures of inferior turbinate involved lateralization followed by resection of about half of the posterior part of the turbinate with the aid of an endoscope.

The extent of FESS varied according to the extent of disease and surgeon's individual practice, but usually classic FESS steps were followed.

Postoperative

All patients received systemic antibiotics (amoxicillin plus clavulanic acid), pain medications, steroids, and alkaline nasal wash after pack removal. Removal of packing was at third day after surgery, Merocel was removed entirely. In contrast, the absorbable packing of CMC or Gelfoam was *in situ*. Remnants of CMC or Gelfoam were suctioned in follow-up visits if were found.

Follow-up assessment

Patients returned for postoperative visits. We scheduled evaluation before removal of pack, during removal (third day), 2 weeks, 4 weeks, 6 weeks, and 12 weeks after surgery.

Subjective assessment

Subjective patients' data were acquired using rated symptoms compared between two sides. All patients were approached to rate their symptoms on a visual

analog scale (VAS) of 0–10, where '0' signifies no symptoms are present, and '10' signifies the most severe symptom. This includes pain, nasal obstruction, and nasal discharge (Table 1 and Fig. 3).

Objective assessment

The patients were evaluated endoscopically after surgery. The operative cavity was evaluated for bleeding, the presence of synechia, crusts, appearance of secretions, and appearance of mucosa (Table 2a-e).

Statistical analysis

Data management and statistical analysis were done using SPSS vs. 25 (IBM, Armonk, New York, USA). Numerical data were summarized as medians and ranges. Comparisons between both groups were done using Wilcoxon test for numerical data. Categorical data were compared using χ^2 test or Fisher's exact test if appropriate. All *P* values were two sided. *P* values less than 0.05 were considered significant.

Results

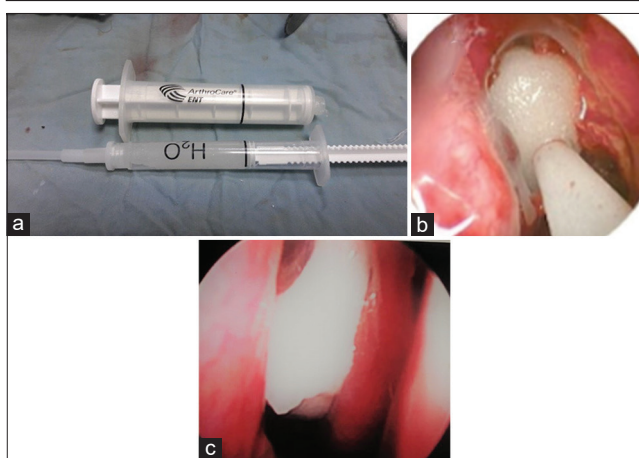
A total of 40 patients were included in this study, comprising 25 (62.5%) males and 15 (37.5%) females, having an age range from 15 to 45, with a mean age of 30 years (Table 3A).

The presenting clinical symptoms in patients of our study are nasal obstruction presented in 20 (50.0%)

Table 1 Grading scale for subjective assessment

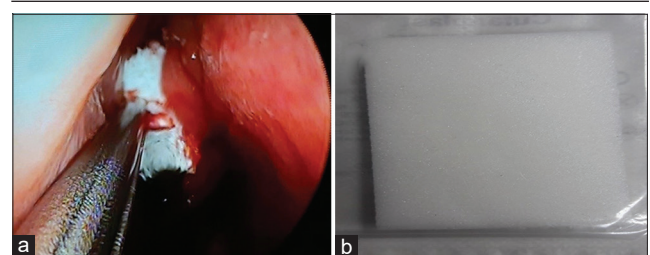
Criteria	Score
Pain	
No	0
Light	1-4
Moderate	5-6
Intolerable	7-10
Nasal obstruction	
No	0
Mild	1
Moderate	2
Severe	3

Figure 1



(a) Gross picture of sinufoam gel preparation. (b) Sinufoam after dissolving during infusion into nasal cavity. (c) Endoscopic view of sinufoam in the operative cavity.

Figure 2



(a) Endoscopic view of gelfoam. (b) Gross picture of gelfoam.

Table 2: Grading scores for objective assessment

Score	Criteria
(a) Grading score for bleeding	
0	No bleeding
1	Minimal (confined to nasal cavity)
2	Moderate (bleeding out of nasal cavity) (cottonoids soaked with phenylephrine hydrochloride)
3	Severe (repacking with merocele)
(b) Grading score for adhesions	
0	No
1	Mild (visible, easy to detach)
2	Moderate (hard to detach)
3	Severe (need synechiolysis)
(c) Grading score for crustations	
0	No
1	Mild
2	Moderate
3	Sever
(d) Grading score for discharge	
0	No
1	Mild (scanty mucopurulent discharge)
2	Moderate (gross mucopurulent discharge)
3	Severe (profuse mucopurulent discharge)
(e) Grading score for Mucosal edema	
0	No
1	Mild (no obvious cavity reduction, spacious maxillary sinus)
2	Moderate (obvious reduction with narrowing sinus orifice)
3	Middle turbinate exposed to lateral wall of nasal cavity
Age	30±7
Sex [n (%)]	
Male	25 (62.5)
Female	15 (37.5)

General characteristics of study population (n=40).

patients, nasal discharge presented in 15 (37.5%) patients, headache presented in 15 (37.5%) patients, hyposmia presented in 10 (25.0%) patients, facial pain presented in 20 (50.0%) patients, and postnasal discharge presented in 15 (37.5%) patients.

The most frequent endoscopic finding was discharge with no polypi (40.0%), whereas the least frequent was hypertrophied inferior turbinate (HIT) (5.0%).

The most frequent operation done was FESS (75.0%) (Table 3B).

The absorbable packing material (group I) was randomly assigned to 25 right nasal cavities (62.5%) and 15 left nasal cavities (37.5%). The nonabsorbable (group II) was assigned accordingly in 25 left and 15 right cavities (Fig. 4).

Subjective assessment

All 40 patients answered the VAS about pain before pack removal, during removal, and follow-up visits.

Before removal of pack

On the absorbable side (group I).

Table 3a: General characteristics of study population (n=40)

Age	Mean±SD 30±7		
Sex	Male	n %	25 (62.5%)
	Female	n %	15 (37.5%)

Table 3B: Operations done of study population

Operations	n (%)
FESS	30 (75.0)
Septoplasty	3 (7.5)
Septoturbino-plasty	5 (12.5)
Turbinectomy	2 (5.0)

FESS, functional endoscopic sinus surgery.

Pain score measured 1 h postoperatively, ranged from 0 to 7 (median 4), 3 h ranged from 0 to 7 (median 7), 12 h ranged from 0 to 7 (median 3), 24 h ranged from 0 to 4 (median 2), and 48 h ranged from 0 to 4 (median 0). On Merocele side (group II), pain score measured 1 h postoperatively ranged from 5 to 9 (median 7), 3 h ranged from 5 to 9 (median 7), 12 h ranged from 4 to 7 (median 6), 24 h ranged from 0 to 7 (median 5), and 48 h ranged 0 to 7 (median 5). There was a highly significant difference, with P value less than 0.001 (Fig. 5a).

During removal of the pack, the absorbable packed sides had lower pain scores (ranged from 0 to 4) than

Merocel packed ones (ranged from 6 to 10), median 0 vs 7, with *P* value less than 0.001.

During follow-up visits

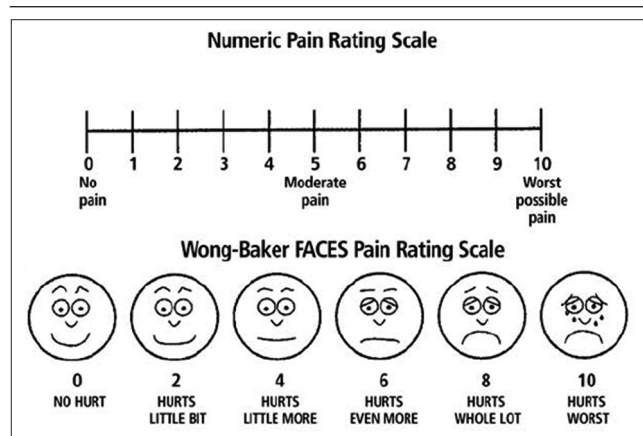
On the absorbable side, there were lower pain scores, which ranged from 0 to 5 (median 1) after 1 week, ranged from 0 to 5 (median 1) after 2 weeks, ranged from 0 to 3 (median 0) after 4 weeks, ranged from 0 to 1 (median 0) after 6 weeks, and was 0 in all patients after 12 weeks. However, on the Merocel side, the pain scores ranged from 0 to 8 (median 7) after 1 week, ranged from 0 to 7 (median 5) after 2 weeks, ranged from 0 to 5 (median 3) after 4 weeks, ranged from 0 to 5 (median 1), and ranged from 0 to 5 (median 0) after 12 weeks. There was a highly significant difference, with *P* value less than 0.001 (Table 4 and Fig. 5b).

Regarding nasal obstruction, patients' discomfort owing to sense of nasal obstruction was much more on the Merocel side. The difference was statistically highly significant (*P*<0.05). However, there was no significant difference in nasal obstruction between two sides before pack removal, at third day, and after 2 weeks, with *P* value greater than 0.05.

However, there was a highly significant difference in nasal obstruction scores between the two sides, which ranged from 0 to 1 on the absorbable side and from 0 to 3 on the Merocel side. There was no statistically significant difference in scores after 2 and 12 weeks postoperatively (Fig. 6).

At 1 week, nasal discharge was significantly higher in Merocel group (37.5%) compared with absorbable group (0%) (*P*<0.001). At 2 weeks, discharge was much more on Merocel side (50.0%) than on the absorbable side (20.0%), with a highly significant difference (*P*=0.005). There was no significant difference after 4, 6, and 12 weeks, with *P* value greater than 0.05 (Table 5).

Figure 3



Visual analog scale of pain.

Objective assessment

Bleeding score was higher on the absorbable side, which ranged from 0 to 3 (median 1), than on the Merocel side, which ranged from 0 to 2 (median 0). This was a significantly higher difference (*P*=0.002). At third day, there was no significant difference between both groups (*P*=0.399). During removal of packing, bleeding ranged from 0 to 1 (median 0) on absorbable side, but it ranged from 0 to 2 (median 1) on Merocel side. This was a highly significant difference (*P*<0.001) (Table 6 and Fig. 7a).

Table 4 Pain score between two groups

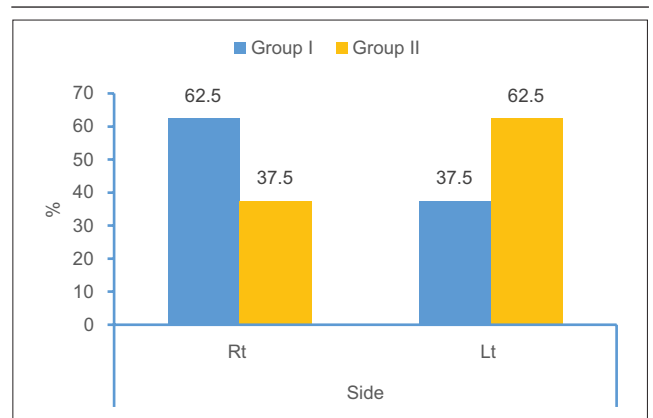
	Group I (n=40)	Group II (n=40)	<i>P</i>
Third day			
Median (IQR)	0 (0-4)	7 (6-10)	<0.001
1 week			
Median (IQR)	1 (0-5)	7 (0-8)	<0.001
2 weeks			
Median (IQR)	1 (0-5)	5 (0-7)	<0.001
4 weeks			
Median (IQR)	0 (0-3)	3 (0-5)	<0.001
6 weeks			
Median (IQR)	0 (0-1)	1 (0-5)	0.001
12 weeks			
Median (IQR)	0	0 (0-5)	<0.001

IQR, interquartile range.

Table 5: Nasal discharge distribution between both groups

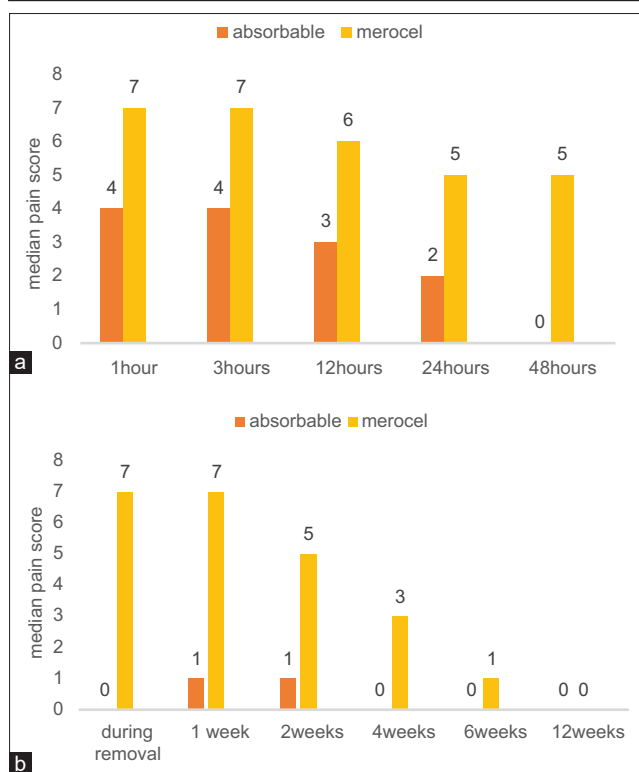
	Absorbable (n=40) [n (%)]	Merocel (n=40) [n (%)]	<i>P</i>
1 week			
Positive	0	15 (37.5)	<0.001
2 weeks			
Positive	8 (20.0)	20 (50.0)	0.005
4 weeks			
Positive	10 (25.0)	14 (35.0)	0.329
6 weeks			
Positive	5 (12.5)	9 (22.5)	0.239
12 weeks			
Positive	2 (5.0)	6 (15.0)	0.263

Figure 4



Side distribution.

Figure 5



(a) Median pain scores (before pack removal) in both groups. (b) Median pain scores on both sides during and after pack removal.

Regarding comparison between 3 materials used

Early postoperatively, 5.0% of patients packed with Gelfoam showed grade 1, 35.0% showed grade 2, and 50.0% showed grade 3. On the Sinufoam side ($n=20$), 15.0% showed grade 1, 10.0% showed grade 2, and no patients showed grade 3. This was a statistically significant difference between Gelfoam and Sinufoam.

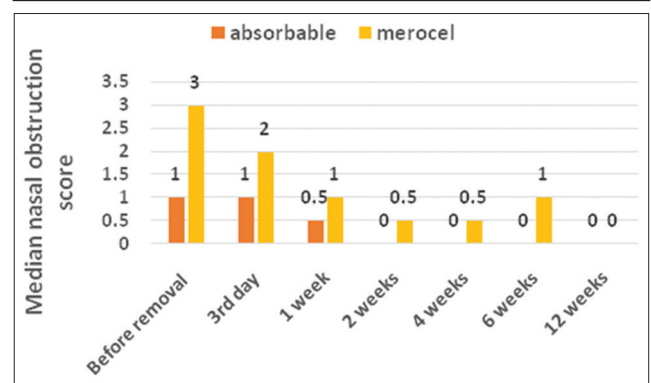
On the Merocele side ($n=40$), 30.0% showed grade 1, 5.0% showed grade 2, and no patients showed grade 3. This was a statistically significant difference between Merocel and Gelfoam. Regarding 3 materials, there was a highly significant difference (all $P<0.001$).

At 3rd day, incidence of bleeding decreased to be 20.0% on Gelfoam sides, 5.0% on Merocel sides, and no cases reported on Sinufoam sides.

During removal, 20.0% of Gelfoam-packed sides showed grade 1. No cases were reported with Sinufoam. However, 42.5% of Merocel packed side showed grade 1 and 40.0% showed grade 2, so Merocel had a higher bleeding frequency compared with Gelfoam and Sinufoam. Regarding the three materials, there was a highly significant difference (all $P<0.001$) (Fig. 7b).

Bleeding was severe (score 3) with turbinoplasty, compared with septoplasty or FESS (score 0, 1, 2).

Figure 6



Median nasal obstruction scores in both groups.

Table 6 Bleeding score between both groups

Bleeding	Absorbable (n=40)	Merocel (n=40)	P
Early postoperative			
Median (IQR)	1 (0-3)	0 (0-2)	0.002
3 rd day			
Median (IQR)	0 (0-1)	0 (0-1)	0.399
During removal			
Median (IQR)	0 (0-1)	1 (0-2)	<0.001
1 week			
Median (IQR)	0 (0-0)	0 (0-0)	1.0
2 weeks			
Median (IQR)	0 (0-0)	0 (0-0)	1.0

IQR, interquartile range.

Patients needed repacking with another pack with more discomfort and more edema.

Crustation score was significantly higher in the Merocel group compared with the absorbable group at 1, 2, 4, 6, and 12 weeks (Table 7 and Fig. 8a).

Regarding comparison between 3 materials used

At 1 week, 35% of Gelfoam group showed mild crustations, and 40% of Sinufoam group showed mild crustations. The Merocel group had higher crustations compared with Sinufoam and Gelfoam, as 52% showed mild crustations and 22% showed severe crustations. This was a statistically highly significant difference (all $P=0.002$).

At 2 weeks, crustations were higher in Gelfoam (60%) compared with Sinufoam (30%). The Merocel group showed higher crustations (70%) compared with Gelfoam and Sinufoam.

At 4 weeks, no difference between the groups was seen (all $P=0.15$).

At 6 weeks, the Merocel showed higher crustations (50%) compared with Gelfoam (35%) and Sinufoam

(5%). This was a statistically significant difference (all $P=0.011$).

At 12 weeks, 10% showed mild crustations in Gelfoam group. The Merocel group showed higher crustations (32.5%) compared with Sinufoam (0%). There was a statistically significant difference (all $P=0.017$) (Fig. 8b).

Crustations were reported with turbinoplasty and septoturbinoplasty more than FESS. Patients with turbinoplasty with/without septoplasty needed more strict instructions about nasal douches. They also associated with mostly moderate to severe degree. However, patients of FESS showed mostly mild to moderate degree.

Adhesions score was significantly higher in the Merocel group, which ranged from 0 to 2 at 2 weeks, and ranged from 0 to 3 at 4, 6, and 12 weeks after surgery, compared with the absorbable group, which ranged from 0 to 1 at 2 and 12 weeks, and ranged from 0 to 2 at 4 and 6 weeks. P value was 0.027, less than 0.001, less than 0.001, and 0.012, respectively. There was no significant difference at 1 and 12 weeks (Fig. 9a).

Regarding comparison between three materials used

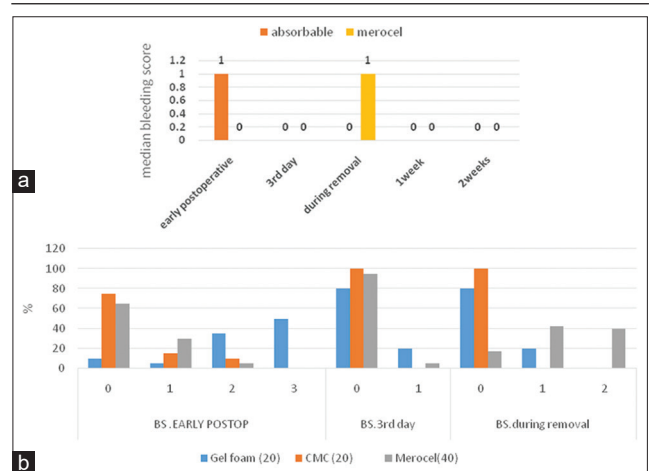
At 1 week, 25% developed mild adhesions in Gelfoam group, and 20% developed mild adhesions in Merocel group. There was a statistically significant difference between Merocele and Sinufoam and between Sinufoam and Gelfoam.

At 2 weeks, 25% developed mild to moderate adhesions in Gelfoam group, and 32.5% developed mild to moderate adhesions in the Merocel group. There was a statistically significant difference between Merocele and Sinufoam and between Sinufoam and Gelfoam.

At 4 weeks, 40% developed mild to moderate adhesion in Gelfoam group, and 10% developed mild to moderate

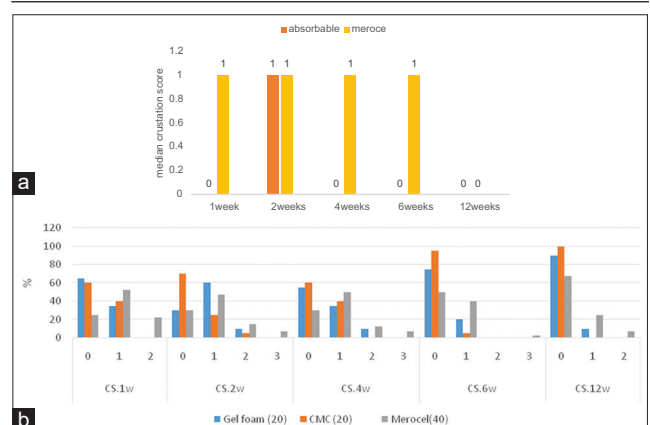
adhesions. The Merocel group has significantly higher adhesions, as 80% developed mild to severe adhesions.

Figure 7



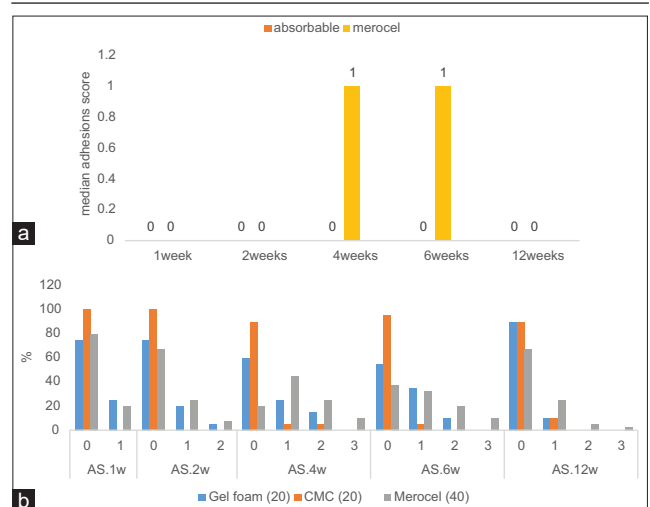
(a) Median bleeding scores in both groups. (b) Bleeding score distribution between materials used.

Figure 8



(a) Crustation score in both groups. (b) Crustations score distribution between materials used.

Figure 9



(a) Median adhesion scores in both groups. (b) Adhesions score distribution between materials used.

Table 7 Crustation score between two groups

Crustation	Absorbable (n=40)	Merocel (n=40)	P
1 week			
Median (IQR)	0 (0-1)	1 (0-2)	<0.001
2 weeks			
Median (IQR)	1 (0-2)	1 (0-3)	0.026
4 weeks			
Median (IQR)	0 (0-2)	1 (0-3)	0.006
6 weeks			
Median (IQR)	0 (0-2)	1 (0-3)	0.001
12 weeks			
Median (IQR)	0 (0-1)	0 (0-2)	0.002

IQR, interquartile range.

At 6 weeks, the Gelfoam group had significantly higher adhesions compared with the Sinufoam group. The Meroceal group developed adhesions with a high frequency (62.5%) compared with the Sinufoam. This was a highly significant difference (all $P=0.001$). There was no significant difference at 12 weeks (Fig. 9b).

Adhesions were much more with turbinoplasty, and needed synechiolysis. However, FESS was associated with minimal scores early postoperatively.

Mucosal edema

Median mucosal edema score was significantly higher in the Meroceal group compared with the absorbable group at 1, 2, and 4 weeks ($P<0.001$). There was no significant difference in mucosal edema score at 6 and 12 weeks ($P>0.05$) (Fig. 10a).

Regarding comparison between three materials used

At 1 and 2 weeks, Meroceal group had significantly higher mucosal edema compared with Gelfoam and Sinufoam. P value was less than 0.001 at 1 week and was 0.001 at 2 weeks.

At 4 weeks, there was a statistically significant difference comparing Meroceal with Gelfoam and Sinufoam. P value was 0.022.

At 6 weeks, the Meroceal group had higher edema (40% of cases) compared with Sinufoam (20% of cases), with significant difference. The Sinufoam was compared with Gelfoam, with a significant difference in-between. There was no statistical difference in comparing all materials (all $P<0.05$).

At 12 weeks, there was no significant difference between materials used ($P=0.34$) (Fig. 10b).

Mucosal edema was more frequent with turbinoplasty with or without septoplasty more than ESS. Then no difference after 4 weeks.

Infection and discharge (I andD)

The only significant difference was at 1 week, with P value less than 0.001, and 2 weeks, with P value of 0.021. At 1 week, infection and discharge scores were significantly higher in the Meroceal than absorbable group. It ranged from 0 to 2 on Meroceal packed sides and from 0 to 0 on absorbable ones (Table 8).

At 1 week, infection and discharge were significantly higher in the Meroceal group (37.5%) compared with the absorbable group (0.0%). P value was less than 0.001.

At 2 weeks, infection and discharge were significantly higher in Meroceal group (50.0%) compared with the absorbable group (20.0%). P value was 0.005.

There was no significant differences between both groups at 4, 6, and 12 weeks (Fig. 11a).

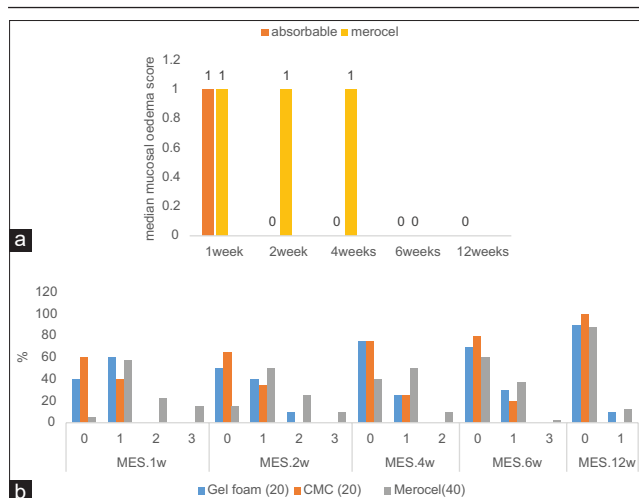
Regarding comparison between three materials used

At 1 week, Meroceal group showed mild infection in 32.5% and moderate in 5.0%, compared with Sinufoam (0.0%) and Gelfoam (0.0%), with P value less than 0.001.

At 2 weeks, Meroceal, Sinufoam, and Gelfoam showed mild infection in 40.0, 16.0, and 3.0%, respectively. Moreover, moderate infection was seen in 10.0, 4.0, and 1.0%, respectively. However, Gelfoam was the only side that showed severe infection. The difference was significantly higher in Meroceal group compared with Gelfoam group and Sinufoam group (all P value 0.001).

At 6 weeks, Sinufoam group did not record any infection. Infection and discharge were statistically significant in Gelfoam group and Meroceal group compared with Sinufoam group (all P value 0.007).

Figure 10



(a) Median mucosal edema score in both groups. (b) Mucosal edema score distribution between materials used.

Table 8 Infection and discharge score between two groups

Infection and discharge	Absorbable (n=40)	Meroceal (n=40)	P
1 week			
Median (IQR)	0 (0-0)	0 (0-2)	<0.001
2 weeks			
Median (IQR)	0 (0-3)	0.5 (0-2)	0.021
4 weeks			
Median (IQR)	0 (0-2)	0 (0-2)	0.377
6 weeks			
Median (IQR)	0 (0-2)	0 (0-2)	0.348
12 weeks			
Median (IQR)	0 (0-2)	0 (0-2)	0.149

IQR, interquartile range.

There was no significant difference in materials at 4 or 12 weeks (all $P>0.05$) (Fig. 11b).

Infection was much more with turbinoplasty, compared with FESS, especially early postoperatively (Figs. 12-16).

Discussion

There is no worldwide estimation framework for outcomes related with nasal packings after surgeries, so the identification of a predominant nasal packing material is troublesome, although certain materials appear to be more viable than others in accomplishing incredible postoperative results [8].

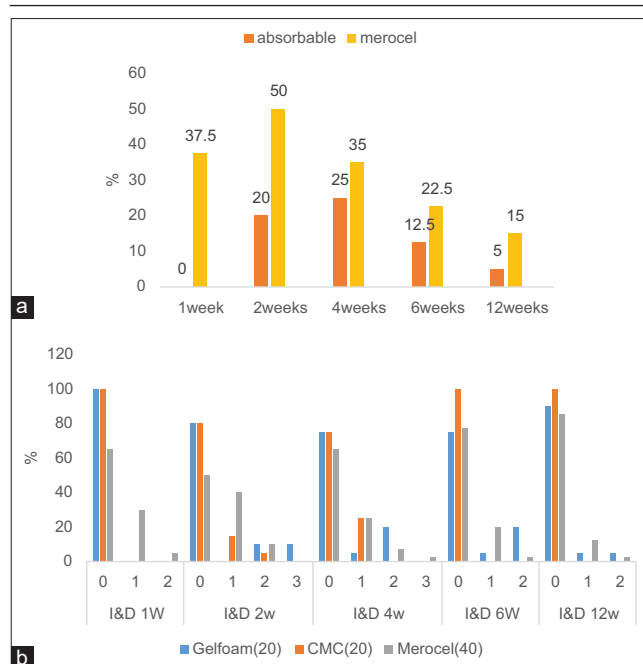
Nasal packing has been used to control bleeding after surgery and helps mucosal healing. Unfortunately, several drawbacks appeared like infection, breathing troubles, and discomfort [9].

Traditional nonabsorbable packing gives hemostasis through pressure and has been well known because of its availability and low cost. However, its removal after surgery is very painful and considered the worst procedure after surgery [10]. They are as yet effective in accomplishing certain results; however, newer absorbable substances might be similarly as successful and keep away from the drawbacks related with nasal packing removal [11].

Emerging absorbable packing materials have put authors in a great debate about which type of nasal packing, whether absorbable or not, has a better effect on subjective and objective outcomes [12].

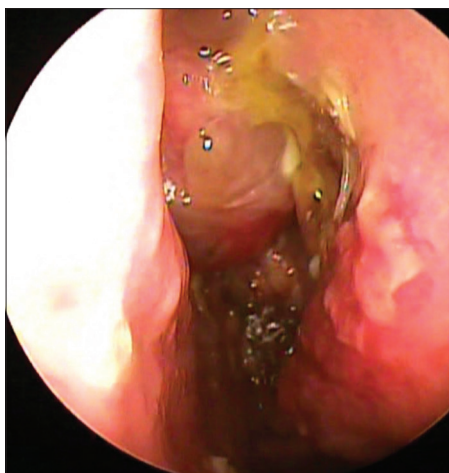
Different materials used in different studies do not allow for selection of certain materials. Moreover, some prefer not using any packs at all. Absorbable packings have been developed in recent years.

Figure 11



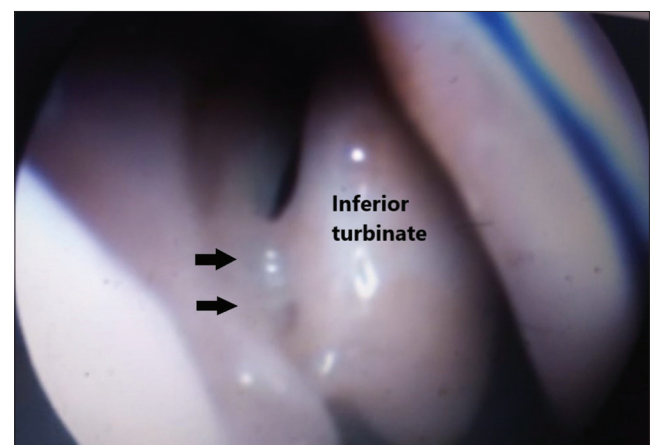
(a) Infection and discharge distribution in both groups. (b) Infection and discharge score distribution between materials.

Figure 13



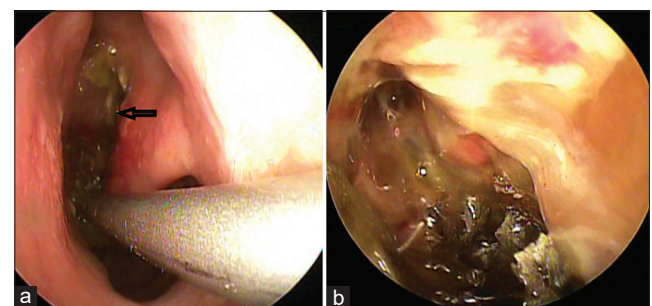
Nasal endoscopy: crustations with Gelfoam after 1 week.

Figure 12



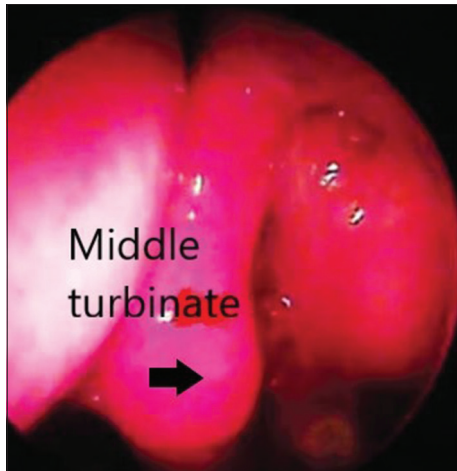
Nasal endoscopy: Synechia at multiple points (severe degree: obstructing) with Gelfoam after 4 weeks. Black arrows: synechia.

Figure 14



(a) Nasal endoscopy: crustations with Merocel after 2 weeks. Black arrow: crustations (b) nasal endoscopy: crustations with Merocel after 4 weeks.

Figure 15



Nasal endoscopy: mucosal edema with Gelfoam after 2 weeks. Black arrow: middle turbinate exposed to lateral wall of nasal cavity denoting severe degree of edema.

These absorbable materials can be one of three categories, dependent on the chemical composition: extracellular matrix-based compounds (gelatin film, gelatin foam, flowable gelatin – thrombin admixture, and hyaluronic acid), coagulation cascade precipitants (fibrin sealant), and natural/synthetic biopolymers (CMC, extracellular matrix, microporous polysaccharide hemispheres, polyethylene glycol, chitosan gel, and polyurethane foam) [8].

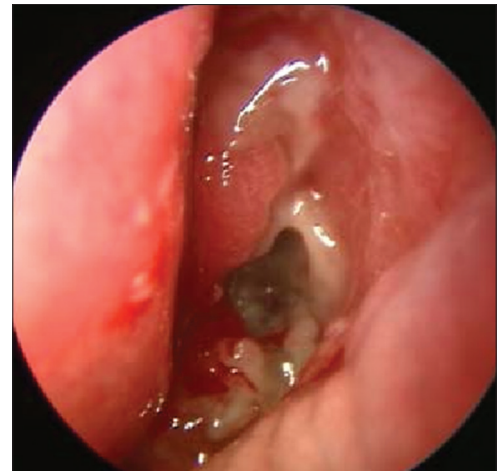There are no known standards for which type of packs to be used, when indicated, and the optimum duration for placement. However, packs should apply pressure, fill spaces, and effectively help hemostatic and reparative process [6]. The most important consideration after nasal surgeries are patient satisfaction, minimize bleeding and discomfort associated with packing removal, and also proper healing of mucosa.

In our study, patients had lower pain score on the absorbable side than on the Merocel side postoperatively, during pack removal, and early follow-up visits.

The estimation of pain presents a few issues, yet VAS can be used to measure pain with high affectability and reproducibility [13]. The absorbable material begins to degrade in the first 24 h after application, and with proper nasal douches using saline, it terminates in 10 days after surgery, therefore does not cause much discomfort and bleeding. Merocel packing causes more damage to nasal mucosa with formation of blood clots around it, therefore causes much discomfort.

Many studies reported that discomfort occurred with Merocel, such as Berlucchi *et al.* [14] who compared it with Merogel (Hyaluronic acid); Lu and Zhang [15] and Wang *et al.* [9] who compared it with Nasopore;

Figure 16



Nasal endoscopy: remnants of Sinufoam after 7 days with mild oozing and no crustations.

and also Leunig *et al.* [16], who detected that there was no difference between CMC packing and no packing at all. Nasopore was also compared with Merocel after FESS by Shoman *et al.* [17] and after septoplasty by Kim *et al.* [18], Yilmaz *et al.* [19], and Romano *et al.* [20].

Subjective parameters such as nasal blockage and discharge were also assessed and were generally lower for the absorbable side.

Nasal obstruction showed no statistically significant difference between both sides at third day and 2 weeks postoperatively. This was caused by the start of resorption of the packing which completed at 7–10 days. Nasal obstruction was much more on the Merocel side because of much mucosal edema and secretions. Nasal discharge was much more on the Merocel side with a statistically highly significant difference at first 2 weeks after surgery and then showed no difference between absorbable and nonabsorbable. The same observations have been reported by Al-Madani *et al.* [21], Berlucchi *et al.* [14], Wang *et al.* [9], Kim *et al.* [18], and Yilmaz *et al.* [19].

This study demonstrated that absorbable packing does not significantly reduce postoperative bleeding. Bleeding was significantly higher on the absorbable side early postoperative, and then no significant difference between both sides at third day. On Gelfoam side, bleeding was significantly higher compared with Sinufoam and Merocel (90 vs 25 and 35%, respectively). The Merocel group showed higher bleeding incidence compared with Sinufoam and Gelfoam during removal (82.5 vs 0 and 20%, respectively). As there was no need to remove the absorbable packing, no mucosal injury occurred, so no significant bleeding was recorded.

This is consistent with the results of Lu and Zhang [5], who did not report any difference between Merocel and absorbable pack (AquacelAg). Moreover, Saedi *et al.* [22] showed that there was no significant difference between Merocel and no packing. Frienkiel *et al.* [23] found no difference for hemostasis between hyaluronic acid and no packing. Another study by Shoman *et al.* [17] compared Nasopore with Merocel placed in a vinyl glove finger and found no significant difference. Cho *et al.* [24] compared Merocel with absorbable Cutanplast and reported more significant bleeding on removal. Karkos *et al.* [25] evaluated CMC Sinu-Knit (small dry pack, mixed with saline before use) and found oozing early postoperative, but no interventions were needed.

On the contrary, the better effect of biodegradable materials on hemostasis was reported. Stankiewicz [26] stated that Floseal was better compared with Merocel. Gall *et al.* [27] found Floseal (gelatin-thrombin admixture) to be a better hemostatic pack compared with no packing. Beyea and Rotenberg [28] reported the same result with Floseal, when its capabilities were compared with a plant-based polysaccharide (HemoStase; Cryolife Inc., Kennesaw, Georgia). Al-Madani *et al.* [21] reported the same hemostatic effect with different absorbable materials used (gelfoam, surgiflo, and sinufoam). Moreover, Kastl *et al.* [7] showed that oxidized cellulose powder is more effective than PVA in controlling bleeding. Kim *et al.* [18] showed that 18.8% of those packed with absorbable synthetic polyurethane foam following FESS had bleeding compared with 81% of the Merocel group. Additionally, Romano *et al.* [20] showed the same result with the Nasopore.

Regarding crustations, the absorbable side recorded significantly lower scores than the Merocel. At fourth week, no significant difference was recorded. This can perhaps be explained by the fact that there is no need for removal of the absorbable packs, so there is less crusting and secretions. Later, crusts disappear. This agrees with Romano *et al.* [20] and Shoman *et al.* [17].

In this study, there was no significant difference in first week and 12 weeks regarding adhesion formations between absorbable and nonabsorbable packed sides. The difference was at 2, 4, and 6 weeks. Merocel had higher adhesion scores than the absorbable ones. This perhaps was due to complete resorption of materials with no remnants and respect of regular intense nasal rinsing during recovery period.

This agrees with Romano *et al.* [20] who found reduction of adhesions in Nasopore group. Hu *et al.* [29] found that there was a decrease in the rate of synechia among patients who got absorbable packings compared with

those who received no packing. Berlucchi *et al.* [14] performed a prospective randomized controlled study looking at the effects of Merogel and standard nonabsorbable packing at 2, 4, and 12 weeks after ESS in 66 patients. They found lower rates of adhesions formation in the Merogel group at both 4 and 12 weeks after the operation.

In contrast, Chandra *et al.* [30] performed a randomized controlled trial contrasting the effects of Floseal and thrombin-soaked gelatin foam, and they found that Floseal significantly increased adhesion. Baumann and Caversaccio [31] in a prospective nonrandomized study showed that there was a little difference in the rate of synechia between Floseal and Merocel. Wang *et al.* [9] showed that the absorbable nasal packing was not associated with a significantly lower risk of synechia after FESS compared with traditional nasal packing. Miller *et al.* [32] in a randomized, controlled study stated that the rate of synechia formation in both groups at about 2 months after the operation was nearly the equivalent. Al-Madani *et al.* [21] showed similar results.

Regarding CMC, Szczygielski *et al.* [5] compared it with no packing. CMC foam performed similarly to PVA sheathed in a latex glove finger for hemostasis and wound healing. Kastl *et al.* [7] performed a prospective study comparing CMC-gel or Sinu-knit with no packs after FESS. There were no differences in patient comfort (nasal obstruction, headache, pressure, and sleep disturbance), wound healing (crustations, adhesions, granulations, and wound closure), and postoperative hemorrhage. Moreover, CMC with dexamethasone was evaluated by Rudmik *et al.* [33] and found it equal to unmedicated CMC for wound healing.

The degree of mucosal edema reflects the degree of operative trauma to mucosa and underlying infection. This can cause temporary obstruction with consequent persistence of postoperative symptoms, so steroids are used to decrease edema.

In this study, edema score was significantly lower on the absorbable side than the Merocel side. Incidence of edema was significantly higher on the Merocel-packed sides compared with Gelfoam and Sinufoam packed sides till the sixth week. Then no difference was recorded. This was against the results reported by Lu and Zhang [15], Wee *et al.* [34], and Al-Madani *et al.* [21].

Another important issue to consider is the significant reduction in infection and discharge at first week on the absorbable side. This is the same observation of Romano *et al.* [19] Wormald *et al.* [33], who reported

that Merogel has no significant benefit in terms of synechia, edema, and infection.

In this study, we compared absorbable with traditional nonabsorbable packing to clarify the effect on wound healing, represented in crustations, adhesions, mucosal edema, and secretions. Long-term follow-up was planned for better long-term results.

Conclusion

Absorbable nasal packings can be a good alternative to traditional packings, as patients' comfort is higher when using Sinufoam or Gelfoam compared with Merocel. This comfort is associated with minimal pain, nasal blockage, and discharge. Using these packs helps to avoid bleeding during removal of traditional packs. However, they are also associated with low ability of hemostasis early postoperatively. Sinufoam and Gelfoam seem to decrease adhesions, crustations, mucosal edema, and infection, especially Sinufoam. This helps for better aeration, repair, and regain of nasal physiology. Gelfoam was associated with a very high incidence of bleeding.

Recommendation

We recommend CMC foam to be a safe, accepted, and well-tolerated alternative to the traditional packings. More studies should be conducted to evaluate hemostatic properties. This is needed to be available with lower cost. Gelfoam needs more studies.

Financial support and sponsorship

Nil.

Conflicts of interest

There are no conflicts of interest.

References

- Weber R, Hochap FEL, Leuwer R, Freigang B, Draf W. Tamponaden und Platzhalter in der endonasalen Chirurgie. *HNO* 2000; 48:240–256.
- Chandra RK, Kern RC. Advantages and disadvantages of topical packing in endoscopic sinus surgery. *Curr Operative Otolaryngol Head Neck Surg* 2004; 12:21–26.
- Ardehali MM, Bastaninejad S. Use of nasal packs and intranasal septal splints following septoplasty. *Int J Oral Maxillofac Surg* 2009; 38:1022–1024.
- Chheda N, Katz AE, Gynizio L, Singer AJ. The pain of nasal tampon removal after nasal surgery: a randomized control trial. *Otolaryngol Head Neck Surg* 2009; 140:215–217.
- Szczygielski K, Rapiejko P, Wojdas A. Use of CMC foam sinus dressing in FESS. *Eur Arch Otorhinolaryngol* 2010; 267:537–540.
- Beule AG, Weber RK, Kaftan H, Hosemann W. Übersicht. Art und Wirkung geläufiger Nasen tamponaden. *Laryngo-Rhino-Otol* 2004; 83:534–551.
- Kastl KG, Betz CS, Siedek V, Leunig A. Control of bleeding following functional endoscopic sinus surgery using carboxymethylated cellulose packing. *Eur Arch Otorhinolaryngol* 2009; 266:1239–1243.
- Massey CJ, Singh A. Advances in absorbable biomaterials and nasal packing. *Otolaryngol Clin North Am* 2017; 50:545–563.
- Wang J, Cai C, Wang S. Merocel versus Nasopore for nasal packing: a meta-analysis of randomized controlled trials. *PLoS One* 2014; 9:e93959.
- Tiemey PA, Samuel D, Patel KS. Audit of patient acceptance of nasal surgery as a day case procedure. *Br J Clin Pract* 1996; 50:357–359.
- Stevens RW. Nasal packing: the rubber pneumatic pack. *AMA Arch Otolaryngol* 1951; 54:191–194.
- Yan M, Zheng D, Li Y, Zheng Q, Chen J, Yang B. Biodegradable nasal packings for endoscopic sinonasal surgery: a systematic review and metaanalysis. *PLoS One* 2014; 9:e115458.
- Bresnihan M, Mehigan B, Curran A. An evaluation of Merocel and Series 5000 nasal packs in patients following nasal surgery: a prospective randomised trial. *Clin Otolaryngol* 2007; 32:352–355.
- Berlucchi M, Castelnuovo P, Vincenzi A, Morra B, Pasquini E. Endoscopic outcomes of resorbable nasal packing after functional endoscopic sinus surgery: a multicenter prospective randomized controlled study. *Eur Arch Otorhinolaryngol* 2009; 266:839–845.
- Lu H, Zhang X. Aquacel Ag used in nasal packing after endoscopic sinus surgery. *Lin Chuang Er Bi Yan Hou Ke Za Zhi* 2005; 19:1059–1060.
- Leunig A, Betz CS, Siedek V, Kastl KG. CMC packing in functional endoscopic sinus surgery: does it affect patient comfort?. *Rhinology* 2009; 47:36–40.
- Shoman N, Gheriani H, Flamer D, Javer A. Prospective, double-blind, randomized trial evaluating patient satisfaction, bleeding, and wound healing using biodegradable synthetic polyurethane foam (NasoPore) as a middle meatal spacer in functional endoscopic sinus surgery. *J Otolaryngol Head Neck Surg* 2009; 38:112–118.
- Kim YS, Kim YH, Kim NH, Kim SH, Kim KR, Kim KS. A prospective, randomized, single-blinded controlled trial on biodegradable synthetic polyurethane foam as a packing material after septoplasty. *Am J Rhinol Allergy* 2011; 25:77–79.
- Yilmaz MS, Guven M, Elicora SS, Kaymaz R. An evaluation of biodegradable synthetic polyurethane foam in patients following septoplasty: a prospective randomized trial. *Otolaryngol Head Neck Surg* 2013; 148:140–144.
- Romano A, Salzano G, Dell'aversana Orabona G, Cama A, Petrocelli M, Piombino P, et al. Califano: comparative study between biodegradable nasopore (BNP) and Merocel hemox10 cm after septo-turbino-plasty procedure. *Eur Rev Med Pharmacol Sci* 2016; 21:669–673.
- Al-Madani A, Youssef A, Abduljalil A, Khalifa H, Zahran M. Effect of biodegradable versus nondegradable nasal packings in the outcome of functional endoscopic sinus surgery: clinical and histopathological study. *Egypt J Otolaryngol* 2018; 34:253–265.
- Saedi B, Sadeghi M, Farschi S. Effect of polyvinyl acetal sponge nasal packing on post-operative care of nasal polyposis patients: a randomised, controlled, partly blinded study. *J Laryngol Otol* 2012; 126:380–384.
- Frenkiel S, Desrosiers MY, Nachtigal D. Use of hylan B gel as a wound dressing after endoscopic sinus surgery. *J Otolaryngol* 2002; 31(Suppl 1):S41–S44.
- Cho KS, Shin SK, Lee JH, Kim JY, Koo SK, Kim YW, et al. The efficacy of Cutanplast nasal packing after endoscopic sinus surgery: a prospective, randomized, controlled trial. *Laryngoscope* 2013; 123:564–568.
- Karkos PD, Thinakararajan T, Goodyear P, et al. Day-case endoscopic sinus surgery using dissolvable haemostatic nasal pack: a pilot study. *Eur Arch Otolaryngol* 2007; 264:1171–1174.
- Stankiewicz JA. Complications of endoscopic sinus surgery. *Otolaryngol Clin North Am* 1989; 22:749–758.
- Gall RM, Witterick IJ, Shargill NS. Control of bleeding in endoscopic sinus surgery: use of a novel gelatin-based hemostatic agent. *J Otolaryngol* 2002; 31:271–274.
- Beyea JA, Rotenberg BW. Comparison of purified plant polysaccharide (HemoStase) versus gelatin-thrombin matrix (FloSeal) in controlling bleeding during sinus surgery: a randomized controlled trial. *Ann Otol Rhinol Laryngol* 2011; 120:495–498.
- Hu KH, Lin KN, Li WT, Huang HM. Effects of Meropack in the middle meatus after functional endoscopic sinus surgery in children with chronic sinusitis. *Int J Pediatr Otorhinolaryngol* 2008; 72:1535–1540.
- Chandra RK, Conley DB, Kern RC. The effect of FloSealon mucosal healing after endoscopic sinus surgery: a comparison with thrombin soaked gelatin foam. *Am J Rhinol* 2003; 17:51–55.

- 31 Baumann A, Caversaccio M. Hemostasis in endoscopic sinus surgery using a specific gelatin-thrombin based agent (FloSeal). *Rhinology* 2003; 41:244–249.
- 32 Miller RS, Steward DL, Tami TA. The clinical effects of hyaluronic acid ester nasal dressing (Merogel) on intranasal wound healing after functional endoscopic sinus surgery. *Otolaryngol Head Neck Surg* 2003; 128:862–869.
- 33 Rudmik L, Mace J, Mechor B. Effect of a dexamethasone SinuFoam™ middle meatal spacer on endoscopic sinus surgery outcomes: a randomized, double-blind, placebo-controlled trial. *Int Forum Allergy Rhinol* 2012; 2:248–251.
- 34 Wee JH, Lee CH, Rhee CS. Comparison between Gelfoam packing and no packing after endoscopic sinus surgery in the same patients. *Eur Arch Otorhinolaryngol* 2012; 269:897–903.
- 35 Wormald PJ, Boustred RN, Le T. A prospective single-blind randomized controlled study of use of hyaluronic acid nasal packs in patients after endoscopic sinus surgery. *Am J Rhinol* 2006; 20:7–10.